

# A rare case of uterine lipo-leiomyoma in a 63-year-old Nigerian woman; a case report

Solaja TO<sup>1, 2</sup>[ID](#), Nwadioku JI<sup>1, 2</sup>[ID](#), Okebalama VC<sup>1</sup>[ID](#), Omokore OA<sup>3</sup>[ID](#), Monday OK<sup>4</sup>[ID](#), Ayeni AA<sup>5</sup>[ID](#), Duru HO<sup>6</sup>[ID](#), Nwudele U<sup>7</sup>[ID](#)

<sup>1</sup>Department of Histopathology, Babcock University Teaching Hospital, Ilishan-Remo, Ogun State, Nigeria

<sup>2</sup>Benjamin Carson (Snr.) College of Health and Medical Sciences, Babcock University, Ilishan-Remo, Ogun State, Nigeria

<sup>3</sup>Babcock University Teaching Hospital, Ilishan-Remo, Ogun State, Nigeria

<sup>4</sup>Emergency Medicine, Norfolk, and Norwich Teaching Hospital, United Kingdom

<sup>5</sup>ENT Unit, Department of Surgery, Babcock University Teaching Hospital, Ilishan-Remo, Ogun State, Nigeria

<sup>6</sup>Anaesthesia Department, Federal Medical Centre Birnin Kebbi, Kebbi State, Nigeria

<sup>7</sup>Emergency Medicine Department, Al Hait Hospital, Kingdom of Saudi Arabia

Submitted: 13<sup>th</sup> July 2023

Accepted: 5<sup>th</sup> September 2023

Published:

[ID](#): Orcid ID

## Abstract

**Background:** Lipo-leiomyoma accounts for about 0.03%-0.2% of uterine tumours. The aetiology of lipo-leiomyoma is unclear, with some suggesting fatty metamorphogenesis and others involving growth factors and oestrogens. Radiological evaluation and histology are necessary for definitive diagnosis. If asymptomatic, no treatment is needed, but surgical resection is performed in symptomatic patients.

**Case Presentation:** This was a case of a 63-year-old Nigerian woman who experienced pelvic pain and heaviness for a year, worsening pelvic pain and distension, and post-menopausal bleeding. Abdominal examinations revealed a pelvic mass, vaginal examination showed no vaginal and cervical lesions, while abdominopelvic ultrasonography (USS) unveiled a hyperechoic mass in the posterior uterus. She underwent a total abdominal hysterectomy and bilateral salpingo-oophorectomy. Histopathological assessment of the samples showed a confirmatory diagnosis of uterine lipo-leiomyoma.

**Conclusion:** Lipo-leiomyoma is a rare, distinct uterine pathology that should be considered a differential diagnosis in post-menopausal women with vaginal bleeding. Total abdominal hysterectomy and bilateral salpingo-oophorectomy are recommended for menopausal women with symptomatic disease to prevent recurrent anaemia and also remove possible sites of the tumour even as the patient is unlikely to conceive again. Histopathological evaluation is crucial for post-menopausal women with coexisting bleeding per vagina.

**Keywords:** Lipo-leiomyoma, post-menopausal vaginal bleeding, Nigerian woman, histology, total hysterectomy, and bilateral salpingo-oophorectomy

## Introduction

Lipo-leiomyoma belongs to a spectrum of disease entities called primary uterine lipid tumours that consist of uterine lipoma, lipo-leiomyoma, and liposarcoma (1). Lipo-leiomyoma was first

described by Lobstein in 1816. Subsequently, Willen and Pounder designated these tumours as "uterine fatty tumours" and subdivided them into "lipoma" and "mixed lipomas/leiomyomas" (lipo-leiomyomas) (2). Lipo-leiomyoma is made up of

Correspondence:  
Okebalama, Victor C  
Department of Histopathology,  
Babcock University Teaching Hospital, Ilishan-Remo,  
Ogun State, Nigeria,  
+2348062995816, [okebalsvictor@gmail.com](mailto:okebalsvictor@gmail.com)

mature adipocytes and muscle fibres; it is a rare, benign neoplasm as they rarely undergo local invasion or distant metastasis. It was previously considered to be a hamartoma, choristoma, connective tissue degeneration, and fatty metamorphosis. It is now regarded as a distinct pathological entity and a variant of uterine leiomyoma (2, 3).

Lipo-leiomyoma is extremely unwanted, accounting for only about 0.03%- 0.2% of uterine tumours (4). Lipo-leiomyomas predominantly occur in the uterus, but extra-uterine tumours in the retroperitoneum, ovaries, and abdominal cavity have been described (1, 5). They occur commonly in perimenopausal and postmenopausal women in their sixth and seventh decades (5).

Uterine lipo-leiomyoma is similar to uterine leiomyoma in presentation and clinical course. Presentation ranges from lack of symptoms to menstrual disturbances, abdominal and/or pelvic pain, a palpable mass, urinary frequency, incontinence, and a sensation of pressure (1). Its commonest location is in the uterine corpus; however, the cervix broad ligament, retroperitoneum, and ovary can also be involved (3). It can be intramural, subserosal or submucosal (3).

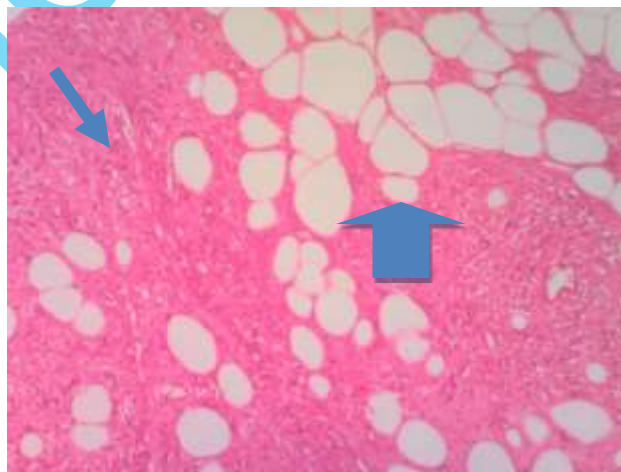
Like uterine leiomyoma, the aetiology of lipo-leiomyoma is unclear. Some works suggested fatty metamorphogenesis of uterine leiomyoma as a possible aetiology, others talked about the roles of growth factors and oestrogen (6). It is difficult to differentiate between leiomyoma and lipoleiomyoma clinically and grossly. Physically, it has a glistening yellow appearance (7).

Although radiological evaluation is needed to map out and define the tumour anatomically, histology

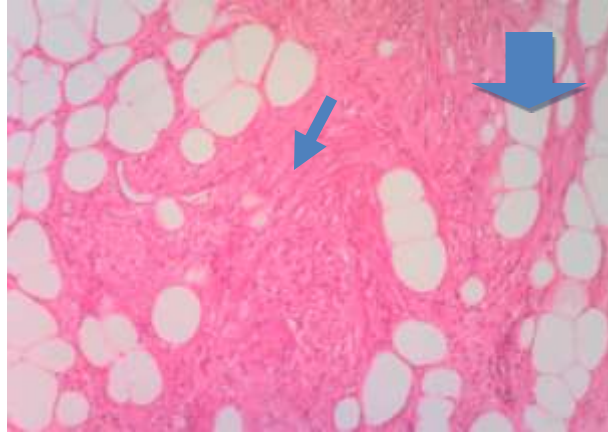
is necessary for a definitive diagnosis (1, 7). Furthermore, lipo-leiomyoma, if asymptomatic, requires no treatment. In symptomatic patients, surgical resection is done to differentiate it from other tumours and where the diagnosis is in doubt (4, 5).

### Case presentation

A 63-year-old post-menopausal retired secondary school teacher, who has had 3 previous pregnancies and deliveries, respectively, presented to our Gynaecology clinic on account of pelvic pain and heaviness of a year duration. Detailed history revealed progressively worsening pelvic pain, pelvic heaviness, abdominal distension, and per vaginal post-menopausal bleeding. She attained menopause at the age of 51 years and has not used hormonal replacement therapy. Abdominal examination revealed a pelvic mass of about 18 weeks gestation. The adnexa were free, and there were no vulval, vaginal, or cervical lesions. Abdominopelvic ultrasonography revealed a hyperechoic mass in the posterior aspect of the body of the uterus measuring 6 cm by 4 cm. The ovaries, fallopian tubes, and cervix were normal. She subsequently had a total abdominal hysterectomy and bilateral salpingo-oophorectomy. The histology of the specimen revealed normal ovaries and fallopian tubes. The cervix showed dense infiltration of the epithelial and sub-epithelial layer by lymphocytes. The uterine mass was composed of proliferating smooth muscle fibres admixed with varying amounts of fibro-collagen and clusters of adipocytes interspersed amongst smooth muscle fibres (Figures 1 & 2). An assessment of Lipo-leiomyoma of the uterus in a menopausal woman was made.



**Figure 1: H and E x40 showing whorls of mature smooth muscle cells (arrows) with interspersed lobules of mature adipocytes (arrowhead) in keeping with Lipo-leiomyoma**



**Figure 2: H and E x40 showing fascicles of mature smooth muscle cells (arrow) with interspersed lobules of mature adipocytes (arrowhead) in keeping with Lipo-leiomyoma**

Follow-up visits one-, three-, and six months following surgical intervention showed normal clinical findings. Additionally, an abdominal USS carried out 6 months after surgery showed no abnormal findings.

#### **Discussion**

Lipo-leiomyoma belongs to a spectrum of primary uterine lipomatous tumours that includes pure lipomas, angioleiomyoma, fibromyolipoma, and liposarcoma (1). It is an extremely rare benign tumour of the uterus seen in perimenopausal women (2, 4, 5). However, it can be seen in atypical sites like the retro peritoneum, cervix, broad ligament, abdominal cavity, and ovaries (5, 8). Mostly asymptomatic, lipo-leiomyoma does not have unique symptomatology. Usually, its presentation when symptomatic overlaps those of uterine leiomyoma with symptoms such as pain in the pelvic region, constipation, unusual vaginal bleeding, abdominal discomfort, or increased frequency of urination seen (3, 8). In the index case, our patient presented with a year's history of pelvic heaviness and pain, abdominal distension, post-menopausal vaginal bleeding, and uterine mass. She was, however, 12 years post-menopausal.

Largely, the aetiopathogenesis of lipo-leiomyoma is unknown. However, theories like metaplasia of immature perivascular mesenchymal cells or smooth muscle cells of leiomyoma to adipocytes, infiltration of the connective tissue by fat, embryonic fat cell misplacement, and influence of oestrogen have been described (4). Also, certain authors have proposed that lipo-leiomyoma patients have defective fat metabolism that is connected to concurrent metabolic diseases (8). Our patient had no history suggestive of a metabolic disorder.

Histologically, lipo-leiomyomas are described as areas of matured adipocyte separated by thin bands of connective tissue and focally interspersed with smooth muscle fibres. Immunohistochemistry profile includes positivity for desmin, h-caldesmon, S100, calretinin, smooth muscle actin (SMA), S-100, and estrogen receptor-positive (ER-positive), but human melanoma black (HMB-45), CD34, and mouse double minute 2 (MDM2) negative (1, 9). Our patient's histology findings were in tandem with the literature. However, immunohistochemistry was not done.

Despite most diagnoses of lipo-leiomyoma being an incidental finding and the difficulty in differentiating it from uterine leiomyomas and other pelvic neoplasms (including malignancies), it is important to radiologically distinguish benign tumours from malignant ones on imaging (9) even as radiologic investigations remains crucial in the diagnosis of lipo-leiomyoma. Abdominal ultrasonography is usually the first modality of choice in lipo-leiomyoma (8). In line with the literature, our patient had abdominal ultrasonography which showed a well-circumscribed mass that contained predominantly fat tissues. Furthermore, abdominal computed tomography and magnetic resonance imaging can help determine the origin topography, number of tumours, fat content, and delineation of anatomically contiguous structures (8). However, they were not done for our patient due to financial constraints.

Since most cases of lipo-leiomyomas are asymptomatic and incidental diagnosis they are mostly managed conservatively. Surgical excision is advised when it is symptomatic, diagnosis is unclear and malignancy is of concern. The prognosis of lipo-leiomyomas is generally

excellent with rare recurrences (8). In our case even as supported by literature, we opted for surgical resection as our patient was symptomatic as shown by the recurrent post-menopausal bleeding which was a *que vive* for malignancy and also a risk factor for repeated anaemia. Additionally, our surgical resection of choice was a total abdominal hysterectomy and bilateral salpingo-oophorectomy considering that our patient was post-menopausal, presented with vaginal bleeding which was highly suggestive of malignancy and a confirmatory pre-operative diagnosis was not possible despite an abdominal USS even as the resected areas can serve as sites for the origination of the tumour. The post-surgical and follow-up periods were uneventful as illustrated by normal clinical and abdominopelvic USS findings done 6 months following surgery. Also, she has been symptom-free for more than two years following surgical intervention.

#### **Conclusion:**

Overall, even though lipo-leiomyoma is a very rare, distinct pathology of the corpus uteri, it should be included as an important differential diagnosis of uterine masses in post-menopausal women presenting with vaginal bleeding. Total abdominal hysterectomy and bilateral salpingo-oophorectomy should be considered the best option in menopausal women with symptomatic forms of the disease as the tumour can occur in the uterus, cervix, and ovaries, amongst other sites and to prevent recurring anaemia which is a common disease complication. Furthermore, this case reiterates the importance of histopathological evaluation of all uterine masses more so in post-menopausal women presenting with coexisting bleeding per vagina in whom a malignant lesion would be the most likely initial or presumptive diagnosis.

#### **List of Abbreviations**

SMA: Smooth muscle actin  
ER: Eostrogen receptor  
HMB-45: Human melanoma black  
MDM2: Mouse double minute 2

#### **Declaration**

##### *Ethics approval and consent to participate*

Written informed consent for publication was obtained from the patient whose management is being reported.

##### *Consent for publication*

All the authors gave consent for the publication of the work under the Creative Commons Attribution-Non-Commercial 4.0 license.

##### *Availability of data and materials*

The essential data supporting the findings of this study are available within the article. Additional data are available on request from the corresponding author due to confidential reasons.

##### *Competing interests*

The authors declare that they have no competing interests.

##### *Funding*

No funding.

##### *Author contributions*

All the authors were involved in the management of the patients and conceptualizing the report. OVC, OOA, AAA, DHO and NU wrote the first manuscript. OVC, MOK, STO, and NJI, corrected the manuscript. All the authors agreed on the final manuscript. The manuscript has been read and approved by all the authors.

##### *Acknowledgements*

We acknowledge the hospital authorities for the opportunity to manage the patient and the patient for allowing us report the case.

#### **References**

1. Bosoteanu M, Vodă RI, Orasanu CI, Aschie M, Enciu M, Baltatescu GI. A case of giant mesenchymal uterine tumour: Lipoleiomyoma. *The American Journal of Case Reports*. 2022;23:e934913-1. <https://doi.org/10.12659/AJCR.934913>
2. Sharma S, Mandal AK. Uterine lipoleiomyoma: A five-year clinicopathological study. *Ann Woman Child Health*. 2016;2(2):A22-26.
3. Manjula, C. P., Simon, N. M., Manjula CP, Simon NM, Venkatesh K, Muneer F, Hemalata M, R. R. A six-year study of leiomyomata with emphasis on lipoleiomyoma. *Int J Res Med Sci*. 2018;7(1):199-204. <https://doi.org/10.18203/2320-6012.ijrms20185380>
4. Adhlakha B, Devdhar S, Chaudhary A, Gupta V, Gautam R. Uterine Lipoleiomyoma: A Rare Case Report, *IJAR - Indian Journal of Applied Research (IJAR)*, IJAR | World Wide Journals. 2021; XI (XI):50-51. <https://doi.org/10.36106/ijar/0102065>

5. Kim YS, Lee JH. A case report of pelviscopic resection of lipoleiomyoma originating from the uterine cervix in a postmenopausal woman. *Medicine*. 2022; 101(39). <https://doi.org/10.1097/MD.00000000000030665>
6. Karaman E, Çim N, Bulut G, Elçi G, Andıç E, Tekin M, Kulusarı A. A Case of Giant Uterine Lipoleiomyoma Simulating Malignancy. *Case Rep Obstet Gynecol*. 2015;2015: 926961. <https://doi.org/10.1155/2015/926961>
7. Shopov S. Lipoleiomyoma in Myomatous Uterus. *Clinical Case Reports: Open Access*. 2019; 2(2):127. <https://doi.org/10.46527/2582-5038.127>
8. Santamonkunrot, Pornchanit & Kantathavorn, Nuttavut & Nakpalat, Katanyuta. (2022). Uterine Lipoleiomyoma in a Perimenopausal Woman. <https://doi.org/10.21203/rs.3.rs-2309657/v1>
9. Schaefer SL, Strong AL, Bahroloomi S, Han J, Whisman MK, Wilkowski JM, Angeles CV. Large intraperitoneal lipoleiomyoma in a premenopausal woman: a case report. *World J Surg Oncol*. 2021;19(1):144. <https://doi.org/10.1186/s12957-021-02256-9>

aheadofprint